



Open camera or QR reader and scan code to access this article and other resources online.

Novel Approach to Facial Rejuvenation by Treating Cutaneous and Soft Tissue for Wrinkles Reduction: First Experience from Multicenter Clinical Trial

Richard Gentile, MD,^{1,*} and Yael Halaas, MD, FACS²

Abstract

Background: Facial aging is determined by skin quality and the condition of underlying muscles, which contribute to the overall appearance by lifting heavy facial structures.

Objective: This study aims to assess the safety and effectiveness of the novel radiofrequency (RF) and high-intensity facial muscle stimulation (HIFES) technology for treating wrinkles by facial tissue remodeling.

Methods: This trial assessed the 3-month data of 24 subjects seeking facial wrinkles treatment. All subjects received four treatments, with a device utilizing RF and HIFES. The evaluation included a two-dimensional photographs assessment according to the Fitzpatrick Wrinkle and Elastosis Scale (FWES) and a three-dimensional (3D) photograph analysis for facial appearance. Therapy comfort and subject satisfaction were assessed.

Results: Based on the data of 24 subjects (56.5 ± 2.0 years, skin types I–IV), the significant improvement increased up to 3 months (-2.3 points, $p < 0.001$) post-treatment. 3D photographs analysis documented notable cutaneous and structural rejuvenation and coincided with FWES evaluation, underlining the positive subjective appreciation of the results with 20.4% average wrinkle reduction at 1 month, further increasing to 36.6% wrinkle reduction at 3 months.

Conclusion: Documented by both subjective and objective evaluation tools, the RF and HIFES procedure for facial rejuvenation was found to be effective for treatment of wrinkles and skin texture.

ClinicalTrials.gov Identifier: NCT05519124.

Introduction

In recent years, various noninvasive and minimally invasive procedures have been developed, mainly for skin tightening,^{1–4} primarily utilizing ultrasound, radiofrequency (RF), or laser energy. The RF modality has become widely adopted due to its ability to induce production of new collagen and elastin fibrils while enhancing the existing connective tissue structures, and

cellular metabolism.⁵ Nonetheless, when it comes to facial appearance, counteracting only the signs of skin aging is part of the solution.^{6–9} The loss of density of underlying muscles plays an important role in overall facial appearance.¹⁰

The direct relationship between facial muscles and skin appearance is based on the muscle toning effect that improves the density and quality of facial muscles, hence

¹Gentile Facial Plastic and Aesthetic Laser Center, Cleveland Clinic, Akron General Hospital, Youngstown, Ohio, USA.

²Private Practice, New York, New York, USA.

*Address correspondence to: Richard Gentile, MD, Gentile Facial Plastic and Aesthetic Laser Center, Cleveland Clinic, Akron General Hospital, 821 Kentwood, Ste C, Youngstown, OH 44512, USA, Email: dr-gentile@msn.com

KEY POINTS

Question: Is the radiofrequency (RF) and high-intensity facial muscle stimulation (HIFES) technology effective in the treatment of facial wrinkles?

Findings: The significant wrinkle reduction was documented by evaluation of digital photographs using Fitzpatrick Wrinkle and Elastosis Scale and three-dimensional analysis.

Meaning: The findings suggest that the RF and HIFES technology are an effective approach for wrinkle treatment.

making the attached skin firmer and more elastic.¹¹ Weakening of the cheek muscles (especially zygomaticus muscles) can promote midfacial soft tissue descent, resulting in the increased severity of the nasolabial fold, formation of jowls, and loss of jawline contour.¹² Muscle remodeling can help to change the face contour by lifting effect that highly contributes to the overall facial appearance.¹³

To target both skin and facial muscle, monopolar RF and high-intensity facial muscle stimulation (HIFES) technology are combined in the novel device, which uniquely synchronizes both technologies to address the overall facial appearance. The mechanism of RF treatment is based on the oscillating electrical currents that flow through the skin tissue, where they are transformed into heat.^{2,14} The novel HIFES technology generates a strong electrical field that depolarizes the motor neurons innervating the facial elevators: frontalis muscle, zygomaticus major and minor, and risorius muscle.

Depolarization of these motor neurons results in supramaximal contractions of these muscles.^{15,16} The selectivity of the technology enabling the stimulation of only the elevator muscles is ensured by the design of the applicators, which contain multiple segments, whereas the HIFES energy is generated only in certain segments overlying the elevator innervating muscles. The repeated application of HIFES results in the initiation of muscle protein synthesis and may lead to the densification of the muscle tissue and its overall improvement.^{17–21}

As documented in previous research, neocollagenesis and neoeLASTINogenesis are initiated after the RF therapy, and the improvements in skin appearance and properties are usually noticeable a few weeks after the treatment.^{14,22,23} In addition, the heat delivered by RF supports the effect of HIFES through improved blood circulation, which increases nutrient supply,^{24,25} promoting the muscle remodeling and regeneration of existing muscle fibers.^{26,27}

This study aims to evaluate the safety and effectiveness of the novel device for facial wrinkles and rhytides treatment. We hypothesize that this novel treatment may facilitate the natural healing process following the thermal effects of RF and workload from HIFES, conceivably resulting in wrinkle reduction and skin tone improvement.²⁴

Methods

Study population

Twenty-four subjects (1 male and 23 females, for more details see Table 1) were enrolled at two study sites. At the time of enrollment, the inclusion and exclusion criteria and the subject medical history were reviewed. Inclusion criteria were subjects aged 21 years and older, understanding of the investigative nature of the treatment concerning potential benefits and side effects, presence of clearly visible wrinkles in the treatment area, willingness and ability to abstain from partaking in any facial treatments other than the study procedure during study participation, and willingness to comply with the study instruction to return to the clinic for the required visits and to have photographs of their face taken.

Subjects who met any exclusion criteria, such as metal implants, local infection, or unhealed wounds in the treated area, were excluded from participation in the study.

Ethical consideration

This multicenter single-arm open-label interventional study was approved by the Advarra Institutional Review Board, and its conduct adhered to the ethical principles of the 1975 Declaration of Helsinki. All patients voluntarily provided informed consent before any study-related procedure was performed. Each patient was assigned a unique subject identification number for anonymization.

Treatment protocol

All patients received treatments with the novel EMFACE (BTL Industries, Inc., Boston, MA) device using RF and HIFES technology for the noninvasive reduction of wrinkles, rhytides, and overall improvement in facial contours. The treatment was performed on the forehead and both cheeks at the same time using adhesive single-use applicators. Before each therapy, the treatment area was cleared of any cosmetics, lotions, jewelry, and prominent hairs. The treatment administration phase consisted of four 20-min treatment visits, delivered 5–10 days apart. At each therapy, the intensities of RF and HIFES

Table 1. Baseline patient characteristics (N = 24)

	All cases
Patients	24
Gender	
Male	1 (4.2%)
Female	23 (95.8%)
Age (years)	
Mean	56.5 ± 2.0
Range	34–75
Median	59.5
Skin types	
I	1
II	13
III	6
IV	4

stimulation (on a scale of 0%–100%, where RF was set to 100% by default) were adjusted according to the patient's feedback concerning any possible discomfort.

All patients were required to complete all four treatments and three follow-up visits: immediately after the last treatment, at 1-month, and at 3-month follow-up (± 10 days). Patients were monitored and examined for the occurrence of any adverse events throughout the study duration.

Data collection and evaluation

At baseline and all follow-up visits, two-dimensional (2D) photographs of the face were taken and evaluated according to the Fitzpatrick Wrinkle and Elastosis Scale (FWES). Three independent evaluators assigned the FWES score to the subjects' pre- and post-treatment photographs to assess wrinkle severity as per Table 2.

The three-dimensional (3D) automated analysis was performed using two standardized systems to evaluate the severity of wrinkles, skin evenness, and texture. A 3D photographic imaging system LifeViz[®] Mini (QuantifiCare S.A., France) was used to capture facial images of 13 patients that were to be evaluated.²⁸ At baseline and both 1- and 3-month follow-up visits, the 2D photographs were taken from the left, right, and front views of the face at multiple angles, and compiled into a 3D model by using Quantificare software suite. 3D models were evaluated for the wrinkle severity and skin evenness by analyzing the combination of depth, length, and width of the wrinkles in the treated areas according to the subject's age, gender, and skin type.

Every analysis was assigned with a score ranging from -10 to $+10$. A negative score means the wrinkle severity and skin evenness are worse than in the average individual, and positive scores >0 (i.e., average) indicate how much better the patient's result is than in the case of an average individual of similar age, gender, and skin type as a concerned subject.

Similarly, photographs of 11 subjects were taken using the Vectra[®] H2 camera (Canfield Scientific, Inc.), and were analyzed for wrinkle severity and skin texture using the included Sculptor[®] software.²⁹ The results were determined as a score based on the intensity of the measured instance on a scale of 0–100, where 100 means the highest possible score reflecting excellent skin condition.

The 5-point Likert scale Subject Satisfaction Questionnaire (SSQ) was administered after the final treatment and at all follow-up visits to assess patients' satisfaction with the therapy results. The Therapy Comfort Questionnaire including the visual analog scale (0—no pain, 10—maximum bearable pain) and 5-point Likert scale was administered after the final treatment session.

Statistical methods

The descriptive statistic was calculated (mean, standard error mean, and median value). All data were analyzed for statistical significance. Paired variables measured at multiple time points were tested by repeated measures analysis of variance followed by a post hoc Tukey honestly significant difference test used to analyze the significance of observed changes. The significance level was set to $\alpha = 0.05$ (5%).

Results

Out of the recruited 24 subjects (56.5 ± 2.0 years, skin type I–IV), 17 completed the 3-month follow-up visit. All patients received wrinkle treatment with parameters set according to the patient's feedback. During the treatment, the intensities ranged from 50–100% for HIFES and 80–100% for RF.

FWES evaluation

The FWES evaluation resulted in a baseline value of 5.2 ± 0.4 points (class II, median value = 5.0 points). At a 1-month follow-up visit, the FWES score decreased to 3.8 ± 0.5 points (median value = 3.5, -1.4 points, $p < 0.001$; class II). The results peaked 3 months after the last treatment ($p < 0.001$), averaging a score of 2.9 ± 0.4 points (median value = 3.0 points, -2.3 points, class I).

3D analysis

Evaluating 3D photographs with QuantifiCare[®] software, the patient's baseline average wrinkle score was subaverage with -1.3 ± 0.6 points. Gradually, it improved showing an average difference of $+3.1 \pm 0.5$ points ($p < 0.001$) at 1-month follow-up, as shown in Figure 1. The improvement was maintained up to 3 months with an average score increase of $+4.4 \pm 0.6$ points ($p < 0.001$). The skin evenness (3.5 ± 0.4 points at baseline) of the whole face was enhanced on average by $+3.7 \pm 0.5$ points at a

Table 2. Wrinkle severity according to the Fitzpatrick Wrinkle and Elastosis scale

Class	Wrinkling	Score	Description
I	Fine wrinkles	1–3	Mild: fine texture changes with subtly accentuated skin lines
II	Fine-to-moderate depth wrinkles with a moderate number of lines	4–6	Moderate: distinct popular elastosis (individual papules with yellow translucency under direct lighting) and dyschromia
III	Fine-to-deep wrinkles, numerous lines with or without redundant skin folds	7–9	Severe: multipapular and confluent elastosis (thickened, yellow, and pallid) approaching or consistent with cutis rhomboidalis

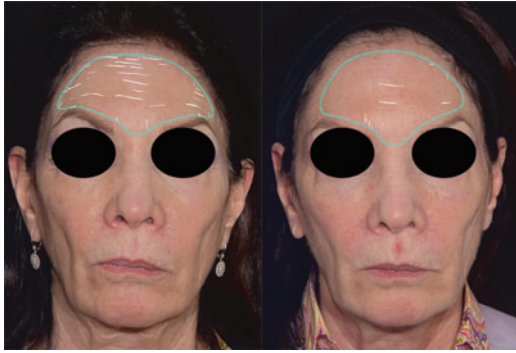

Fig. 1. Seventy-five-year-old patients before (left) and at 1 month after (right) the final treatment with the EMFACE device. Photographs were taken using the 3D photograph imaging system LifeViz[®] Mini (QuantifiCare S.A., France). 3D, three-dimensional.

1-month follow-up visit ($p < 0.001$). At the 3-month follow-up, a significant improvement ($p < 0.001$) by $+5.1 \pm 0.6$ points was achieved.

The photographs evaluated in Vectra Sculptor software analogically showed a wrinkle improvement noticeable from the 1-month follow-up when the score increased by $+11.3 \pm 2.2$ points ($p < 0.001$) against the baseline (53.0 ± 3.7 points). The improvement peaked at 3 months with an average score increase by $+17.6 \pm 2.8$ points ($p < 0.001$). The skin texture (75.0 ± 3.8 points at baseline) was enhanced by $+11.6 \pm 4.1$ points at a 1-month follow-up visit, and by $+17.7 \pm 2.5$ points at 3 months (both $p < 0.001$).

Despite the use of different 3D analysis software tools, desired changes were observed in all subjects with fine or pronounced wrinkles resulting in fuller and lifted cheeks 1 and 3 months after the final treatment as shown in Figures 2 and 3. Average subject's improvement rate was quite similar for both software, achieving 36.8% (QuantifiCare) and 36.5% (Vectra) improvement at 3 months for wrinkles and 24.2% (QuantifiCare) and 26.2% (Vectra) for skin evenness and texture, respectively.

Subject satisfaction and therapy comfort

The majority of patients (87.5%, $N=21$) agreed that the therapy was comfortable and 91.7% ($N=22$) patients reported no or minimal discomfort during the treatment. There were no negative responses from the SSQ evaluation immediately after the treatment. At 1- and 3-month follow-ups, satisfaction with results was high, achieving 95.5% and 95.0%, respectively. In addition, 87.5% of patients reported more lifted and tighter skin after the treatment during the whole study. The lifting effect is demonstrated in Figure 4. No adverse events or treatment-related side effects were observed.

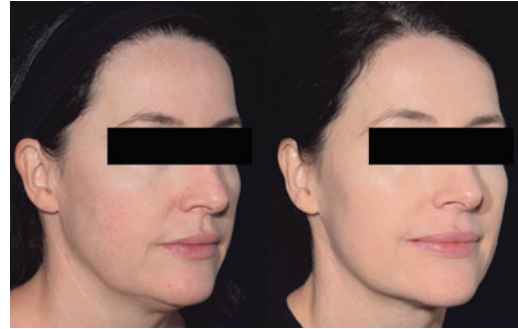

Fig. 2. Forty-six-year-old patients before (left) and at 3 months after (right) the final treatment with the EMFACE device. Photographs were taken using the 3D photograph imaging system LifeViz[®] Mini (QuantifiCare S.A., France).

Discussion

The appearance of facial wrinkles and rhytides was significantly ($p < 0.05$) improved after the treatment using a novel device combining RF and HIFES technologies. The FWES results showed a shift from class II (5.2 ± 0.4 points) to class I (2.9 ± 0.4 points) indicating only fine wrinkles. The 3D analysis demonstrated a significant wrinkle (36.6%) and skin texture (25.2%) improvement maintained up to 3 months. The majority of patients (90.9%) agreed the therapy was comfortable and there were no negative responses from the SSQ. In addition, patients were satisfied especially with the lifting effect visible after the final treatment and with treatment results (83.3%) in general—outcomes leading to minimization of signs of aging.

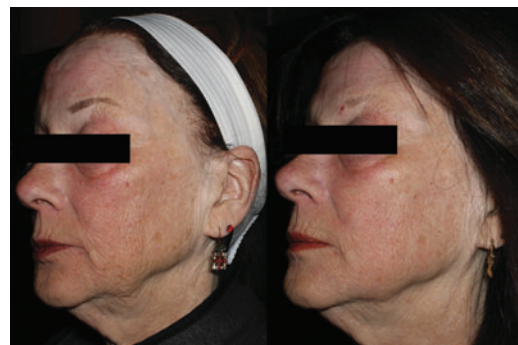

Fig. 3. Sixty-two-year-old patients before (left) and 3 months after (right) the final treatment with the EMFACE device showing wrinkle severity improvement with visible jawline definition.

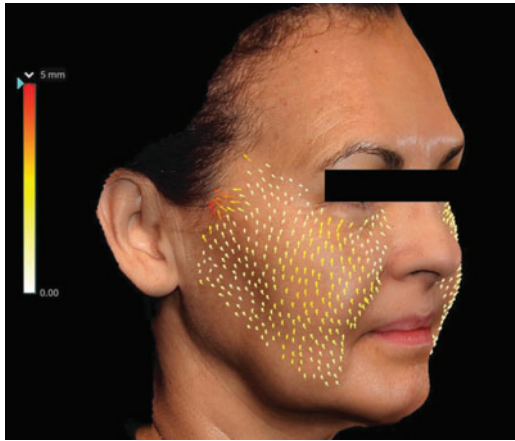


Fig. 4. Sixty-year-old patient at the 1-month follow-up visit after the final treatment with the EMFACE device with pronounced lifting effect on the cheeks. Photographs were taken using the 3D photograph imaging system LifeViz[®] Mini (QuantifiCare S.A., France).

In this study, the skin quality, determined by wrinkle, evenness, and texture analysis, improved most at 3 months. These outcomes corresponded with findings of Kent et al.³⁰ and Goldberg and Lal,³¹ confirming the fact that collagen and elastin structural remodeling within 3 months after the RF treatment resulted in skin rejuvenation. In addition, the outcomes demonstrated by Kinney and Jarosova³² and Halaas³³ presented positive muscle changes, especially densification and overall function improvement shown at the 3 months post-RF+HIFES treatments.

This benefit of synchronized use of RF and HIFES technologies to the overall facial appearance was supported by our findings accompanied by high patients' satisfaction with a lifting effect, reported by 87.5% of the treated subjects. Although our study was not primarily focused on the lifting effect, these findings suggest that remodeling of facial muscles considerably contributes to the lifting of the facial structures. In addition, as heat responsive, the collagen and elastin remodeling was initiated after RF heating and supported the lifting effect by increasing the skin elasticity and tightness.

Current therapies for facial rejuvenation often include invasive surgical facelift procedures, botulinum neurotoxin-based injections, and skin fillers. Despite them being effective, they are still considered (minimally) invasive and could be associated with a number of side effects and drawbacks, such as long recovery, or scarring, and also limited effectiveness on the underlying muscles.³⁴⁻³⁶

The use of a novel device offers a way to overcome most of these disadvantages. The device combines the

synchronized effect of RF on the skin tissue with selective stimulation of the underlying fibromuscular tissue and fascia using HIFES technology. This combination poses as an interesting opportunity for targeting facial wrinkles. Moreover, as documented herein, the combined treatment is fully noninvasive and highly comfortable with minimal or mild discomfort.

To achieve reliable wrinkle improvement evaluation, two methods were used—FWES based on blinded evaluators and 3D automated analysis due to the potential limitations of the former. Overall, the considerable consistency of the FWES and 3D analysis results was documented, evidencing the positive effect of the treatment on wrinkles and skin texture. Also, to include a wide range of patients with well-visible facial wrinkles, subjects of varying ages were enrolled (34–75 years). Nonetheless, desired changes were observed in all subjects with fine or pronounced wrinkles resulting in fuller and lifted cheeks after the treatment, regardless of the demography.

Future research on larger and specific patients' groups, for example, those manifesting a certain degree or severity of wrinkles and rhytids, would be of great value to expound on the effectiveness of the treatment by EMFACE device for wrinkle reduction and to improve facial appearance.

Based on our findings, the EMFACE device may be recommended for the noninvasive treatment of wrinkles and overall facial skin appearance. EMFACE offers a noninvasive, pleasant, and fast alternative to current facial therapies or surgeries.

Conclusion

The treatment by a novel EMFACE device simultaneously delivering RF and HIFES resulted in a significant improvement in overall facial appearance. Based on the outcomes from 3D analysis and FWES evaluation, the procedure leads to decreased facial wrinkle severity (36.6%) and improved skin quality (25.2%). The treatment proved its safety since no adverse events were documented.

Authors' Contributions

Conceptualization of the study was carried out by R.G., methodology was by R.G. and Y.H., formal analysis was by R.G. and Y.H., investigation was done by R.G. and Y.H., resources were taken care by R.G. and Y.H., writing—original draft, was done by R.G., writing—review and editing, was by R.G. and Y.H., and supervision was carried out by R.G. and Y.H.

Author Disclosure Statement

The study was sponsored by BTL Industries. The investigators may be contracted to speak or present this study on behalf of BTL Industries.

Funding Information

This Institutional Review Board-approved study was sponsored by BTL Industries.

References

- Gorgu M, Gokkaya A, Kizilkan J, Karanfil E, Dogan A. Radiofrequency: review of literature. *Turk J Plast Surg.* 2019;27(2):62–72.
- Chilukuri S, Denjean D, Fouque L. Treating multiple body parts for skin laxity and fat deposits using a novel focused radiofrequency device with an ultrasound component: safety and efficacy study. *J Cosmet Dermatol.* 2017;16(4):476–479.
- Park H, Kim E, Kim J, Ro Y, Ko J. High-intensity focused ultrasound for the treatment of wrinkles and skin laxity in seven different facial areas. *Ann Dermatol.* 2015;27(6):688.
- Gold MH, Adelglass J. Evaluation of safety and efficacy of the TriFractional RF technology for treatment of facial wrinkles. *J Cosmet Laser Ther.* 2014;16(1):2–7.
- Meyer PF, de Oliveira P, Silva FKBA, et al. Radiofrequency treatment induces fibroblast growth factor 2 expression and subsequently promotes neocollagenesis and neovascularization in the skin tissue. *Lasers Med Sci.* 2017;32(8):1727–1736.
- Cotofana S, Fratila A, Schenck T, Redka-Swoboda W, Zilinsky I, Pavicic T. The anatomy of the aging face: a review. *Facial Plast Surg.* 2016;32(03):253–260.
- Beer K, Beer J. Overview of facial aging. *Facial Plast Surg.* 2009;25(05):281–284.
- Wong QYA, Chew FT. Defining skin aging and its risk factors: a systematic review and meta-analysis. *Sci Rep.* 2021;11(1):22075.
- Tobin DJ. Introduction to skin aging. *J Tissue Viability.* 2017;26(1):37–46.
- Kahn D, Shaw R. Overview of current thoughts on facial volume and aging. *Facial Plast Surg.* 2010;26(05):350–355.
- Lim HW. Effects of facial exercise for facial muscle strengthening and rejuvenation: systematic review. *J Korean Phys Ther.* 2021;33(6):297–303.
- Joshi K, Hohman MH, Seiger E. SMAS plication facelift. In: *StatPearls.* StatPearls Publishing; 2023. www.ncbi.nlm.nih.gov/books/NBK531458/. Accessed April 26, 2023.
- Abe T, Loenneke JP. The influence of facial muscle training on the facial soft tissue profile: a brief review. *Cosmetics.* 2019;6(3):50.
- Goats GC. Continuous short-wave (radio-frequency) diathermy. *Br J Sports Med.* 1989;23(2):123–127.
- Myers T. Fascial fitness: training in the neuromyofascial web. *IDEA Fit J.* 2011;8(4):36–43.
- Alfen NV, Gilhuis HJ, Keijzers JP, Pillen S, Van Dijk JP. Quantitative facial muscle ultrasound: feasibility and reproducibility. *Muscle Nerve.* 2013;48(3):375–380.
- Silantyeva E, Dragana Z, Ramina S, Evgeniia A, Orazov M. Electromyographic evaluation of the pelvic muscles activity after high-intensity focused electromagnetic procedure and electrical stimulation in women with pelvic floor dysfunction. *Sex Med.* 2020;8(2):282–289.
- Silantyeva E, Zarkovic D, Astafeva E, et al. A comparative study on the effects of high-intensity focused electromagnetic technology and electrostimulation for the treatment of pelvic floor muscles and urinary incontinence in parous women: analysis of posttreatment data. *Female Pelvic Med Reconstr Surg.* 2021;27(4):269–273.
- Moss FP, Leblond CP. Satellite cells as the source of nuclei in muscles of growing rats. *Anat Rec.* 1971;170(4):421–435.
- Schultz E, McCormick KM. Skeletal muscle satellite cells. *Rev Physiol Biochem Pharmacol.* 1994;123:213–257.
- Duncan D, Dinev I. Noninvasive induction of muscle fiber hypertrophy and hyperplasia: effects of high-intensity focused electromagnetic field evaluated in an in-vivo porcine model: a pilot study. *Aesthet Surg J.* 2020;40(5):568–574.
- Tanaka Y, Tsunemi Y, Kawashima M, Tatewaki N, Nishida H. Treatment of skin laxity using multisource, phase-controlled radiofrequency in Asians: visualized 3-dimensional skin tightening results and increase in elastin density shown through histologic investigation. *Dermatol Surg.* 2014;40(7):756–762.
- Yokoyama Y, Akita H, Hasegawa S, Negishi K, Akamatsu H, Matsunaga K. Histologic study of collagen and stem cells after radiofrequency treatment for aging skin. *Dermatol Surg.* 2014;40(4):390–397.
- Malerich SA, Nassar AH, Dorizas AS, Sadick NS. Radiofrequency: an update on latest innovations. *J Drugs Dermatol.* 2014;13(11):1331–1335.
- Gold MH. Noninvasive skin tightening treatment. *J Clin Aesthetic Dermatol.* 2015;8(6):14–18.
- Mauro A. Satellite cell of skeletal muscle fibers. *J Biophys Biochem Cytol.* 1961;9(2):493.
- Halaas Y, Duncan D, Bernardy J, Ondrackova P, Dinev I. Activation of skeletal muscle satellite cells by a device simultaneously applying high-intensity focused electromagnetic technology and novel RF technology: fluorescent microscopy facilitated detection of NCAM/CD56. *Aesthet Surg J.* 2021;41(7):NP939–NP947.
- Almadori A, Speiser S, Ashby I, et al. Portable three-dimensional imaging to monitor small volume enhancement in face, vulva and hand: a comparative study. *J Plast Reconstr Aesthet Surg.* 2022;75:3574–3585.
- Fan W, Guo Y, Hou X, et al. Validation of the portable next-generation VECTRA H2 3D imaging system for periocular anthropometry. *Front Med.* 2022;9:833487.
- Kent D, Fritz K, Salavastru C. Effect of synchronized radiofrequency and novel soft tissue stimulation: histological analysis of connective tissue structural proteins in skin. Presented at Annual Meeting of the American Society for Dermatologic Surgery, San Diego; 2022.
- Goldberg DJ, Lal K. Histological analysis of human skin after radiofrequency synchronized with facial muscle stimulation for wrinkle and laxity treatment. In: *American Society for Dermatologic Surgery (ASDS) Annual Meeting 2022, CO;* 2022.
- Kinney BM, Jarosova R. Animal study investigates an effect of monopolar radiofrequency and novel HIFES technology on cutaneous and structural remodeling. Presented at Annual Meeting of the American Society for Laser Medicine and Surgery, San Diego; 2022.
- Halaas Y. Muscle quality improvement underlines the non-invasive facial remodeling induced by a simultaneous combination of a novel facial muscle stimulation technology with synchronized radiofrequency. Presented at American Academy of Facial Plastic and Reconstructive Surgery, October 19–23, 2022, Washington, DC; 2022.
- Kislevitz M, Lu KB, Wamsley C, Hoopman J, Kenkel J, Akgul Y. Novel use of non-invasive devices and microbiopsies to assess facial skin rejuvenation following laser treatment. *Lasers Surg Med.* 2020;52(9):822–830.
- Smith MA, Ferris T, Nahar KV, Sharma M. Non-traditional and non-invasive approaches in facial rejuvenation: a brief review. *Cosmetics.* 2020;7(1):10.
- Huang J, Yu W, Zhang Z, Chen X, Biskup E. Clinical and histological studies of suborbital wrinkles treated with fractional bipolar radiofrequency. *Rejuvenation Res.* 2018;21(2):117–122.